The subpyloric space

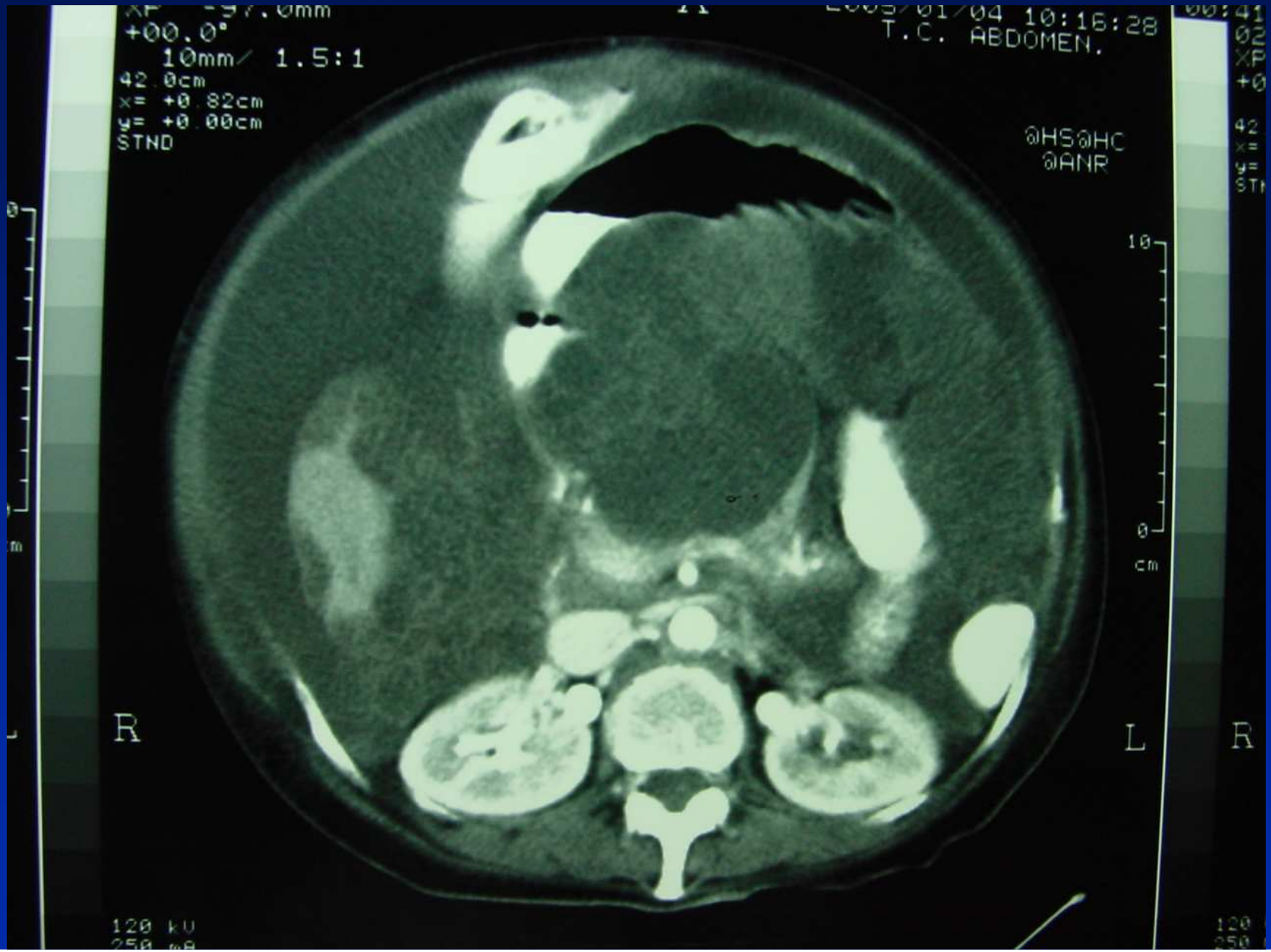

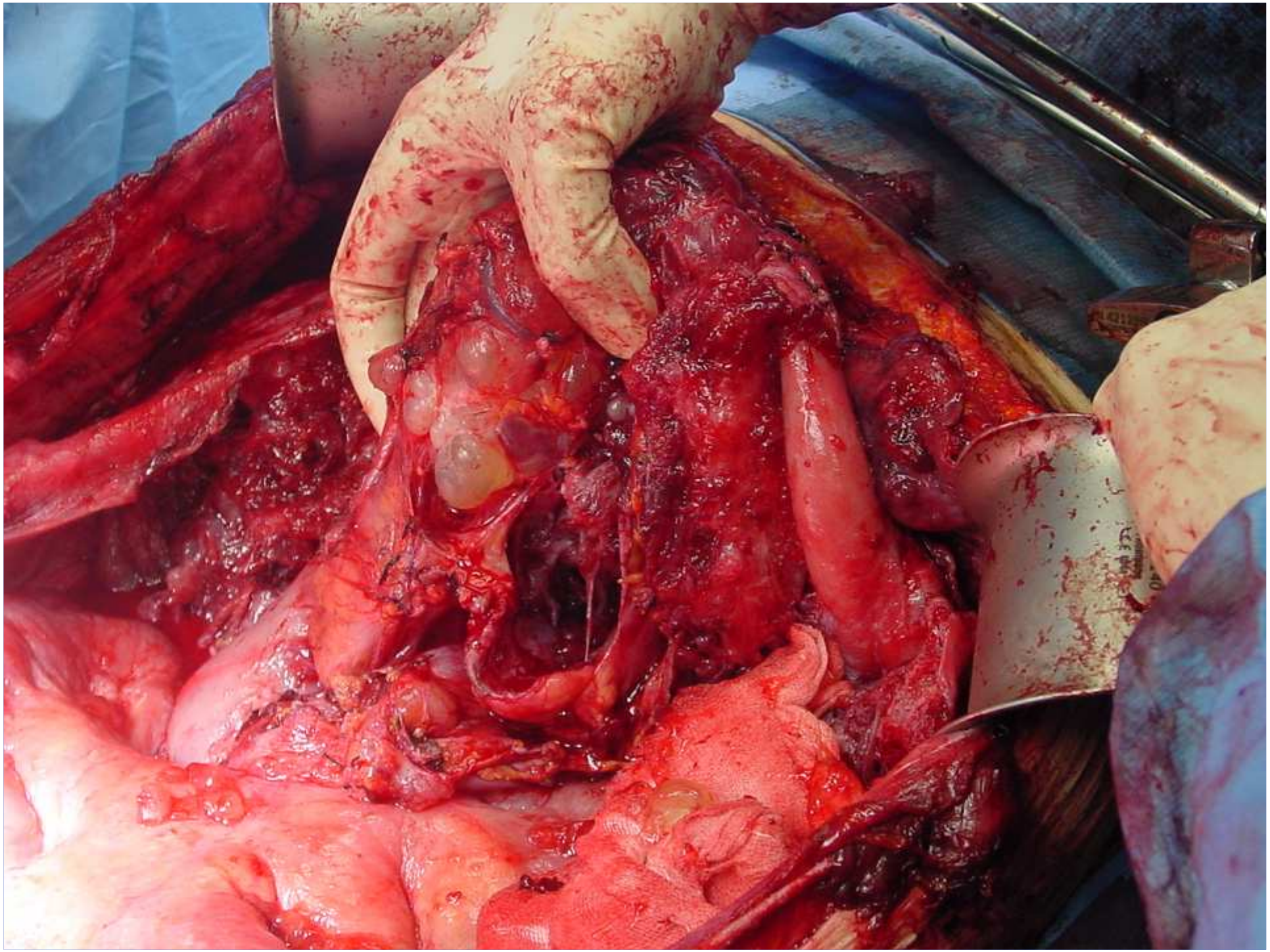

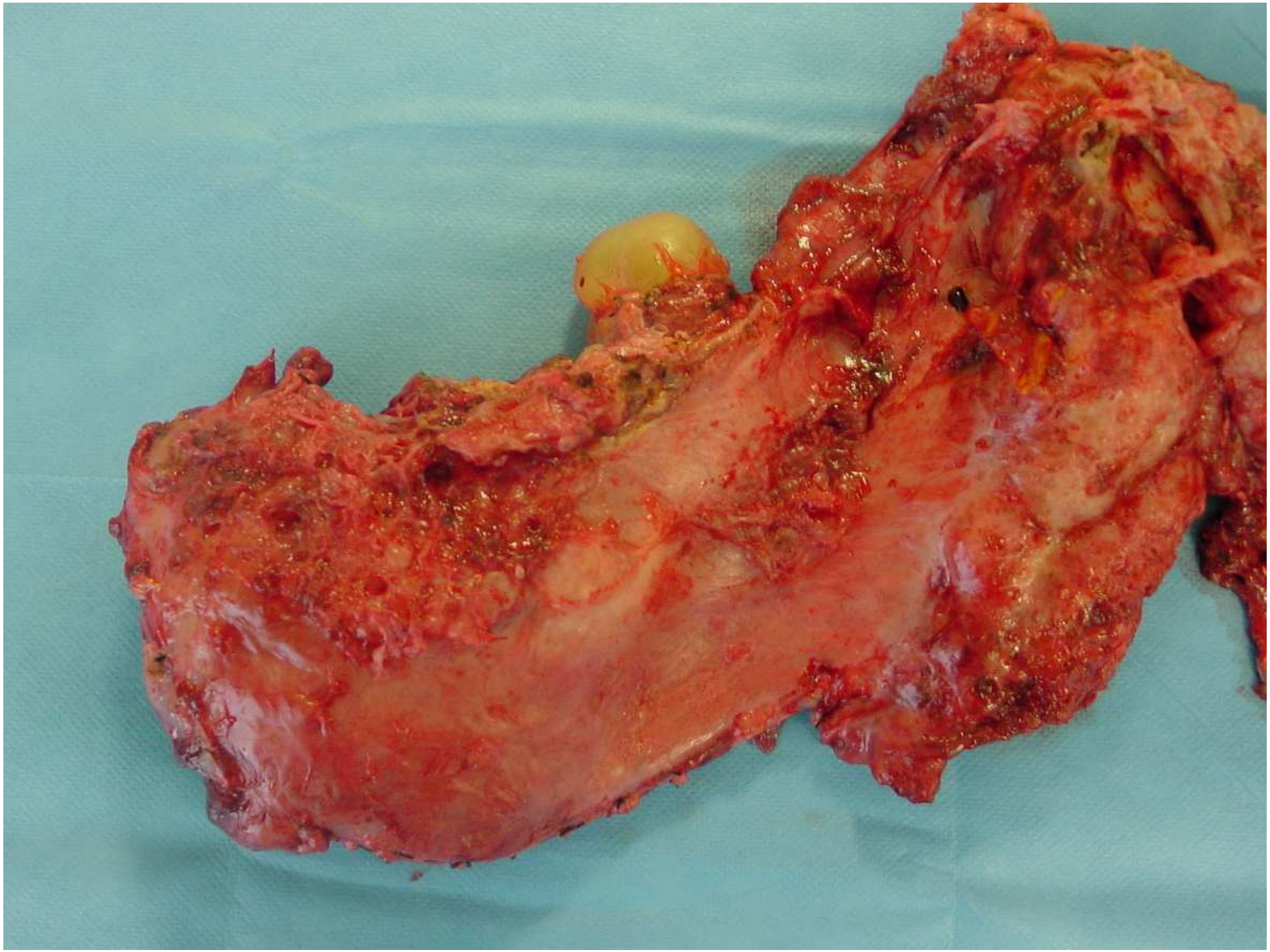

The superior recess of the omental bursa

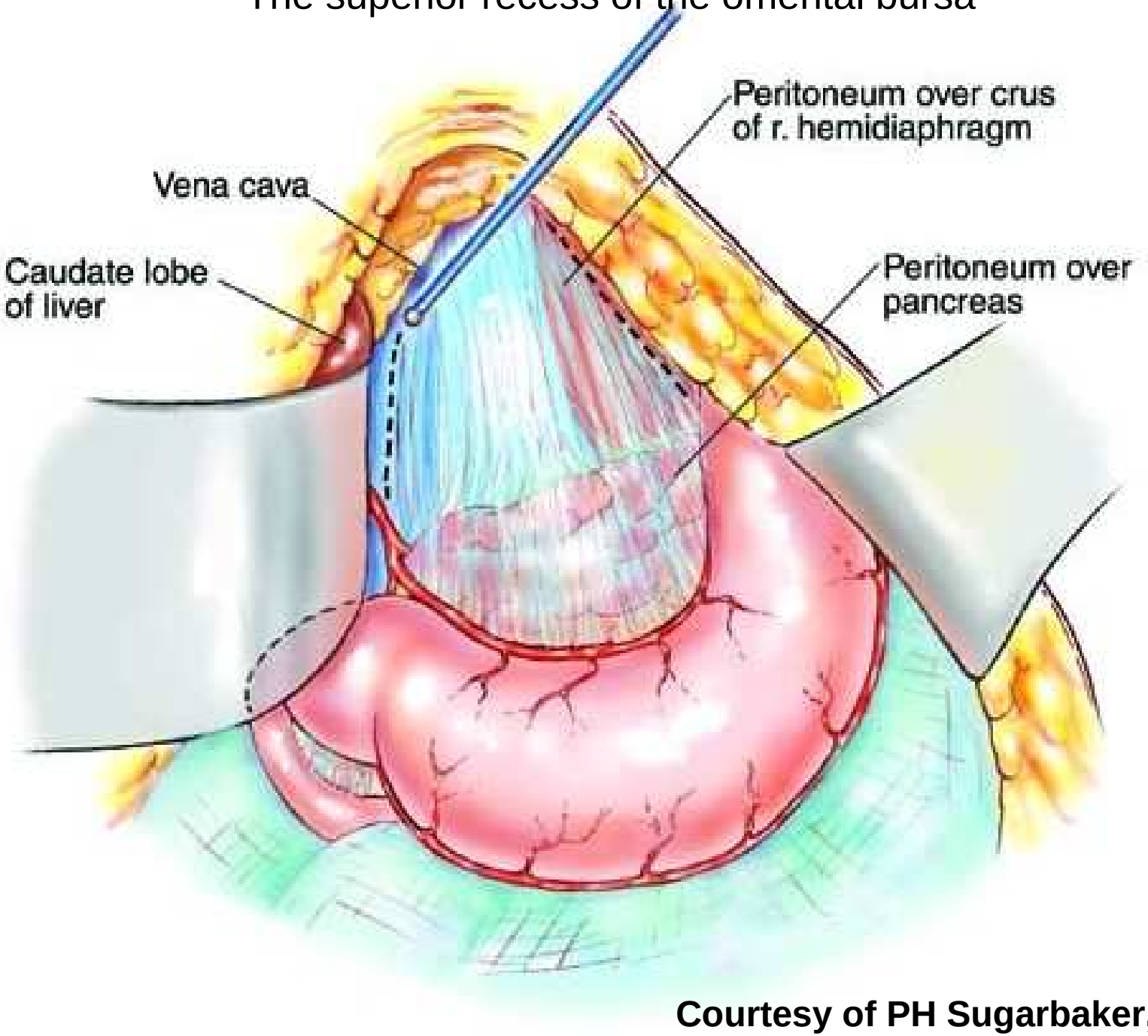

Courtesy of PH Sugarbaker, MD

The superior recess of the omental bursa

The superior recess of the omental bursa

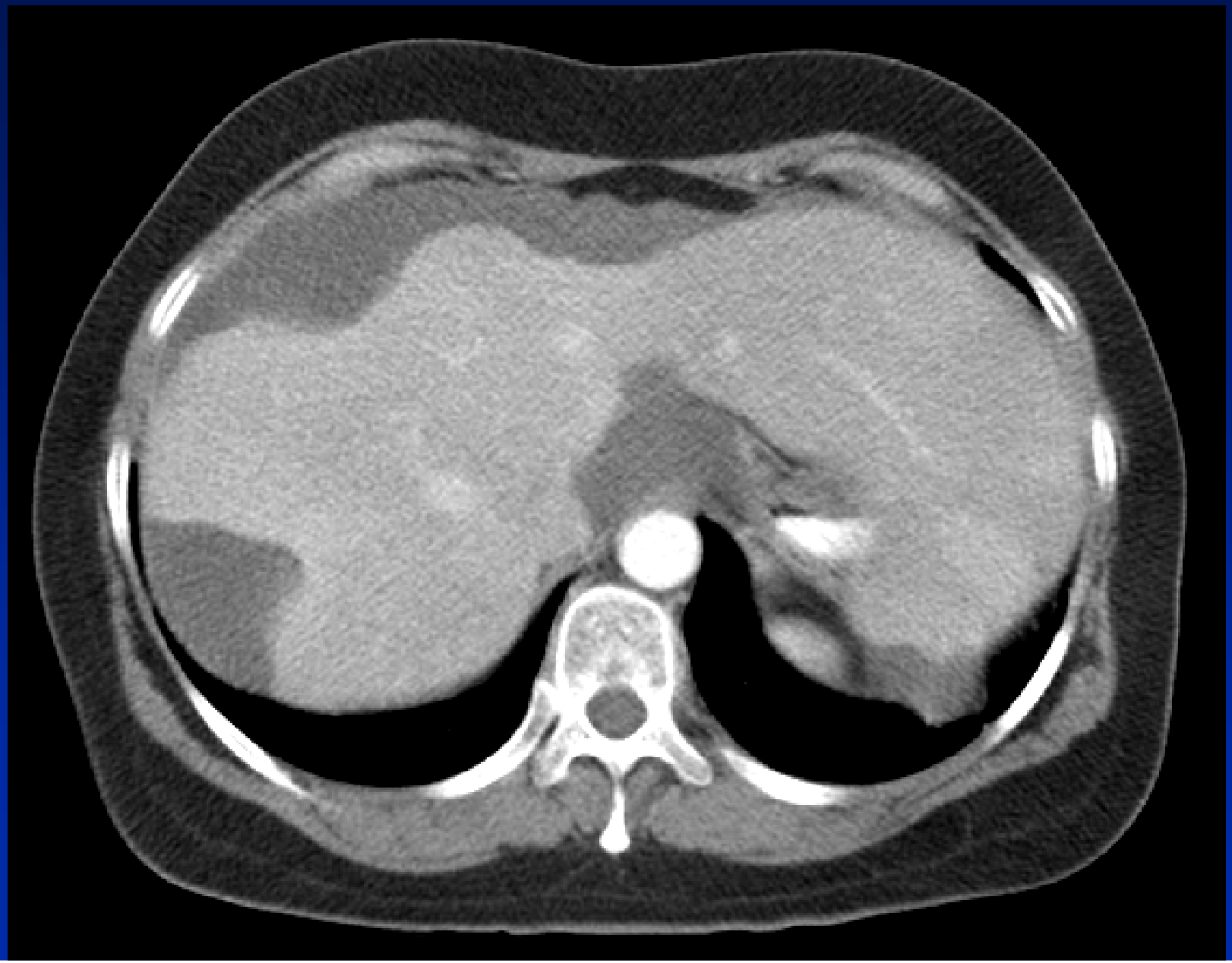

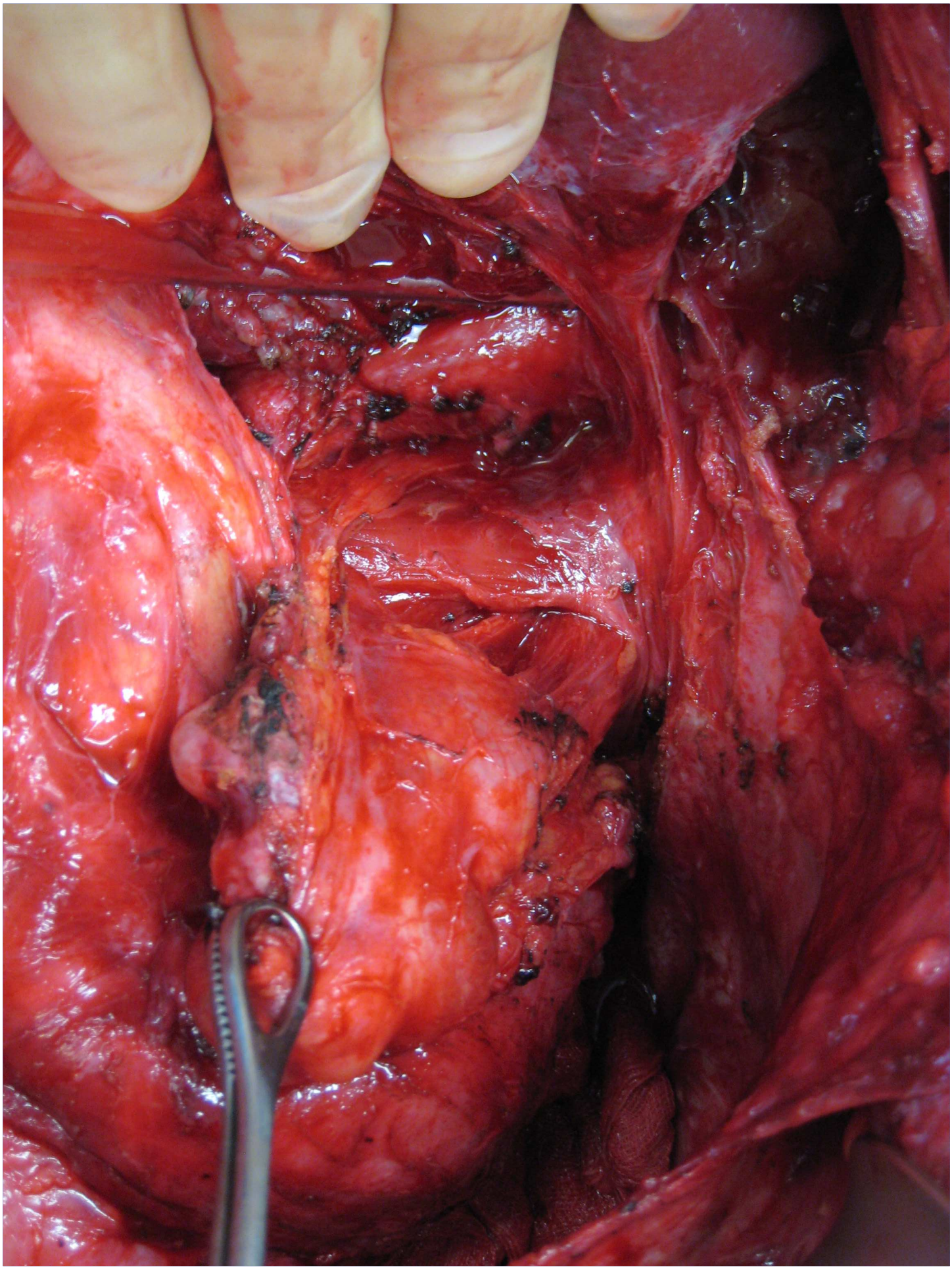

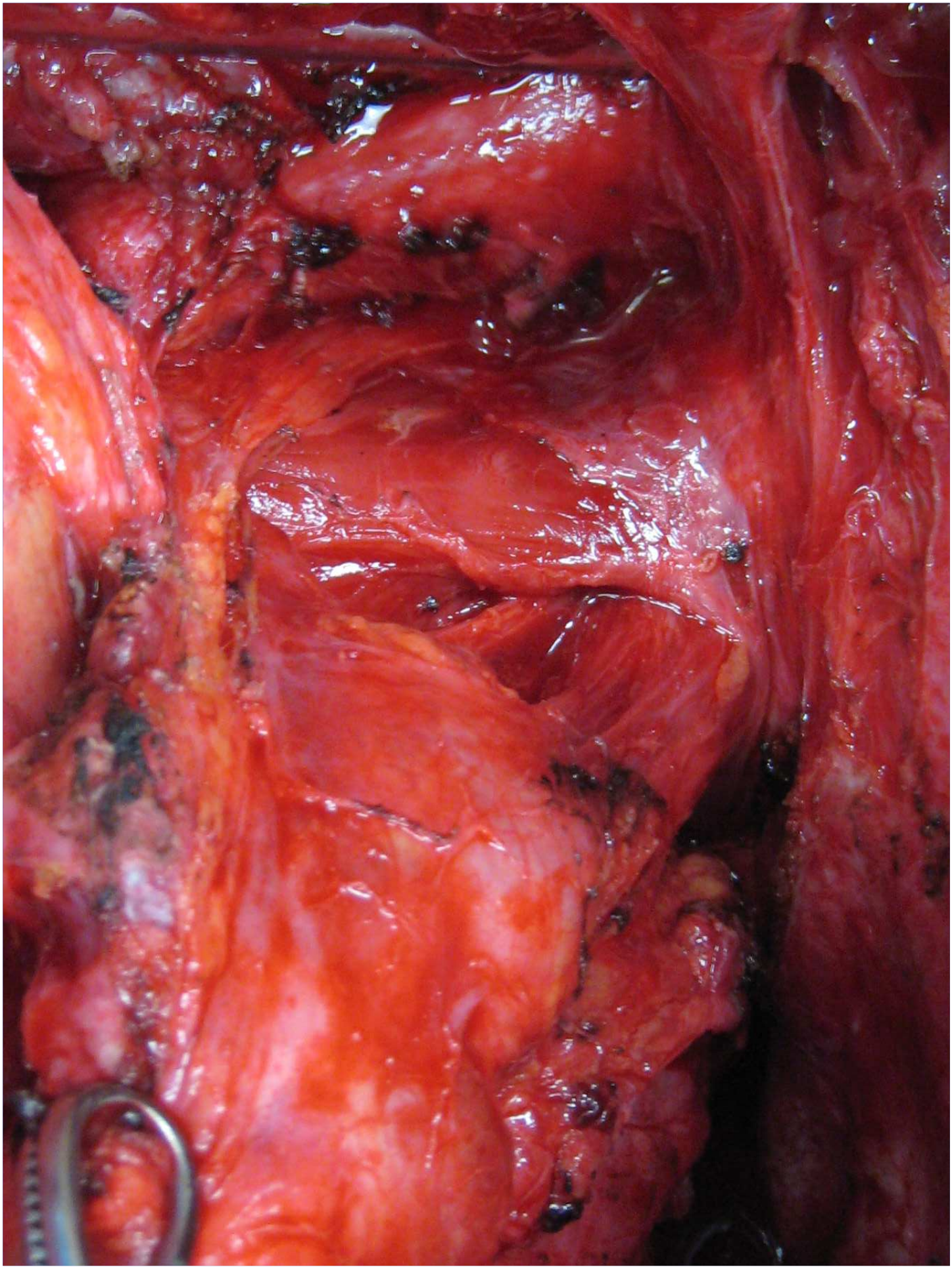

The small bowel

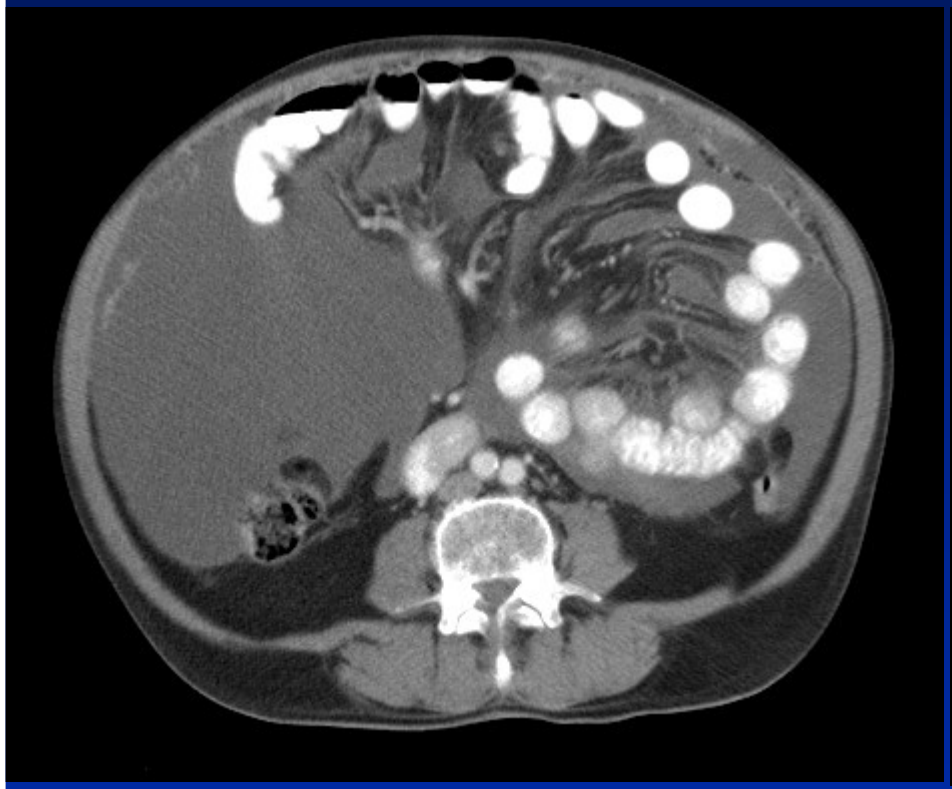

The small bowel mesentery

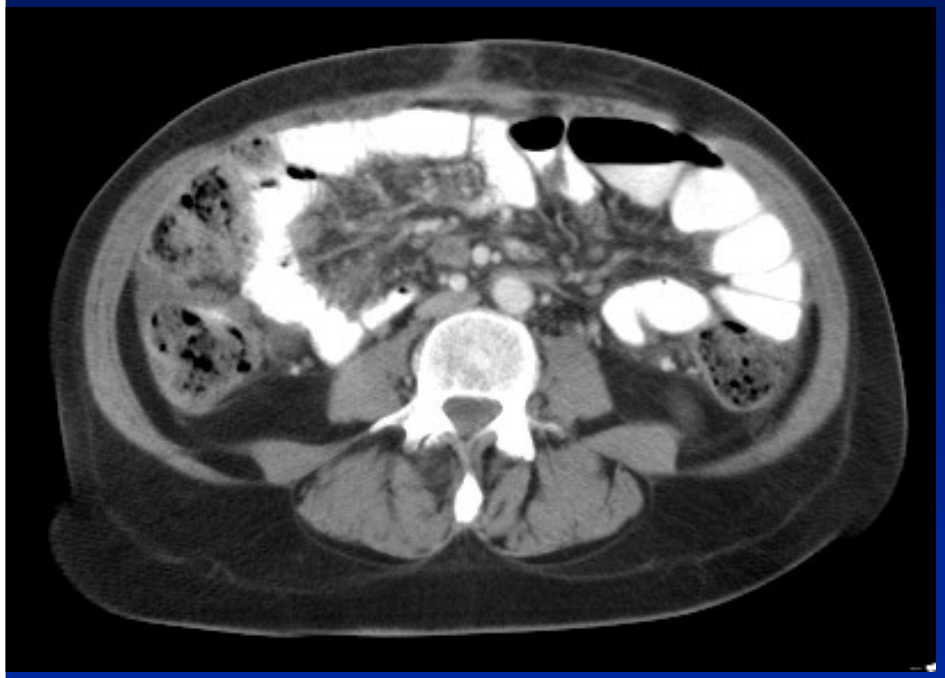

The small bowel

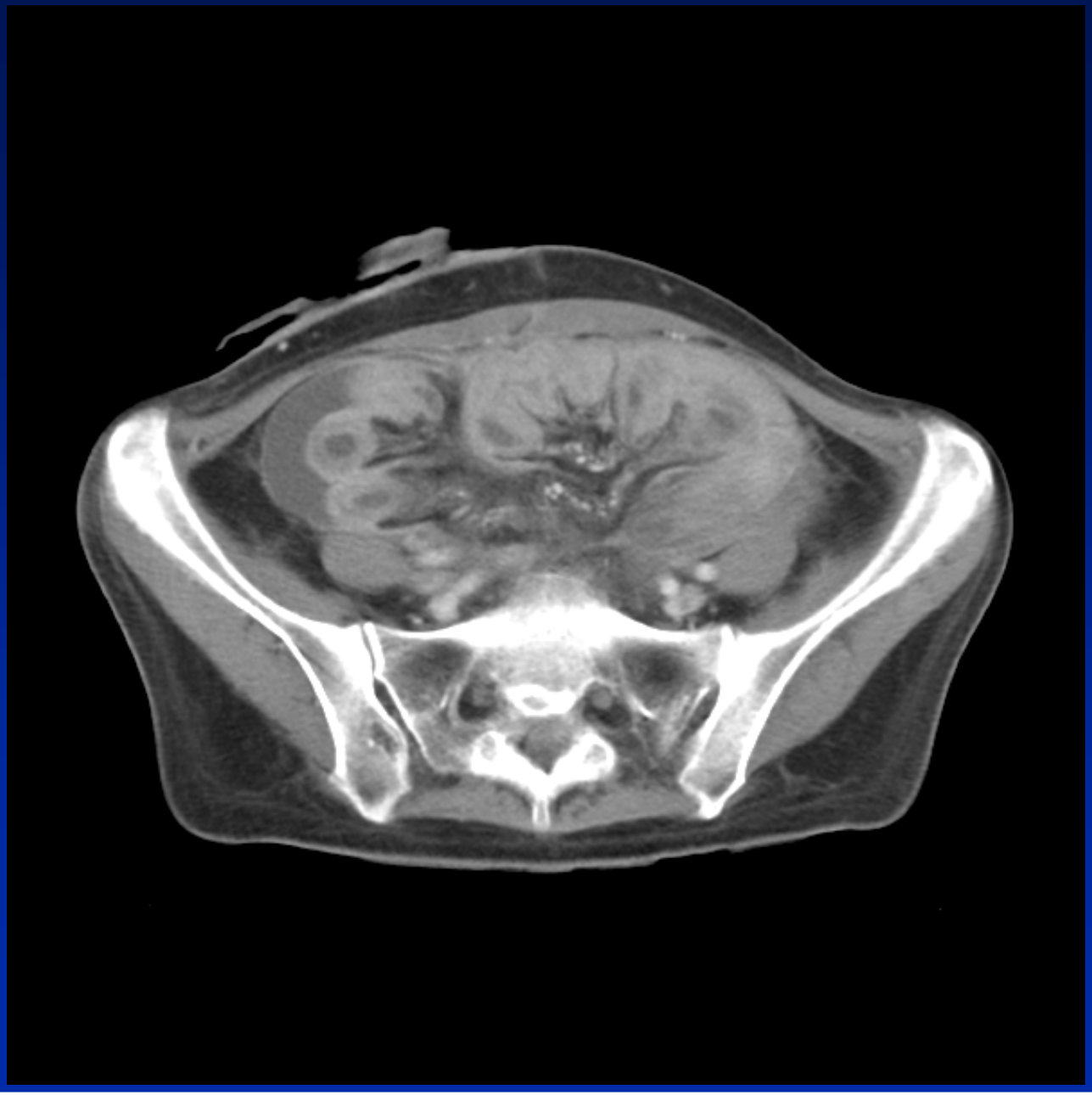


10mm/ 1.5:1
ABDOMEN.
STND
R
L
120 kV
250 mA
0.8 sec

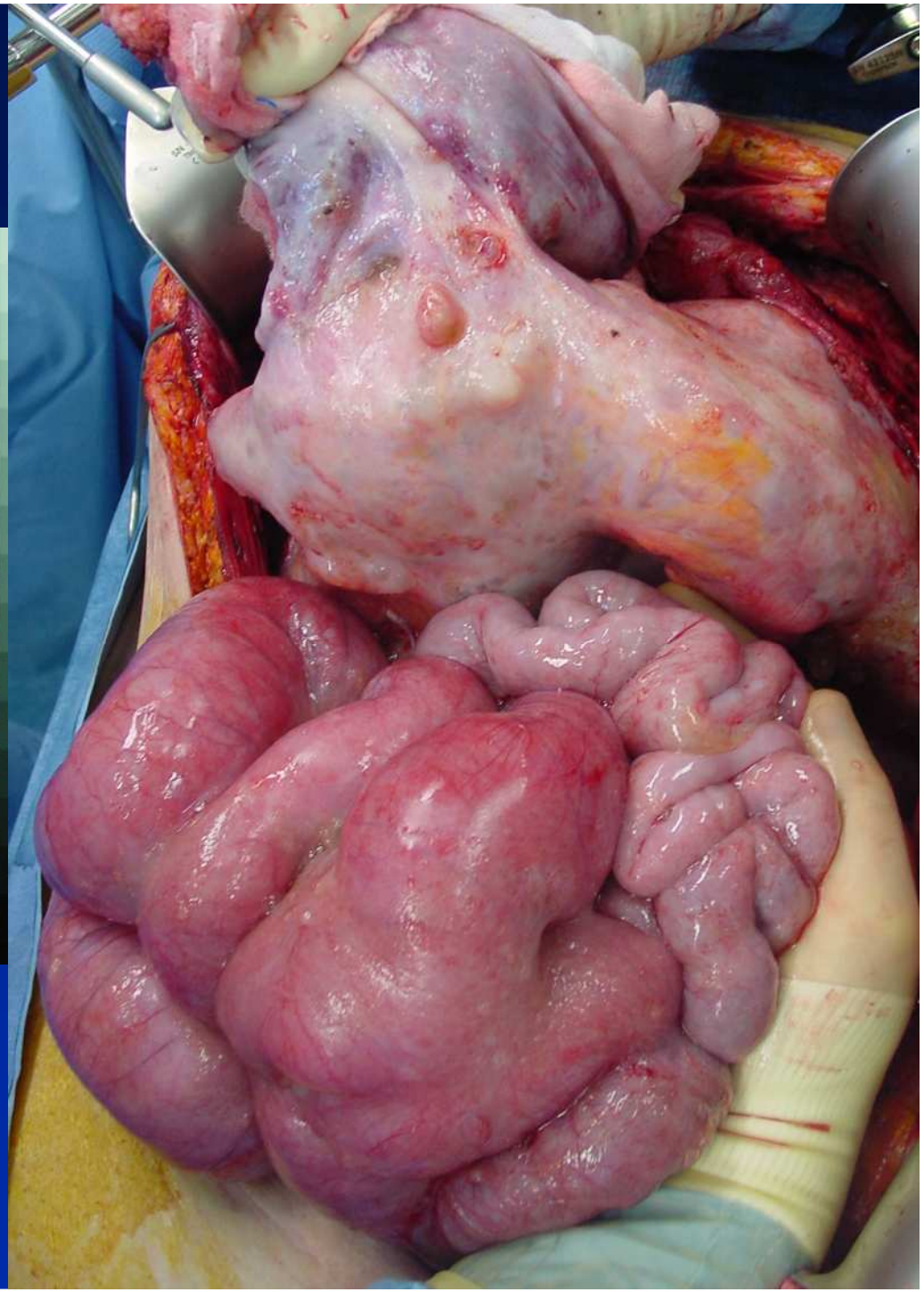

PET/CT scan in peritoneal carcinomatosis

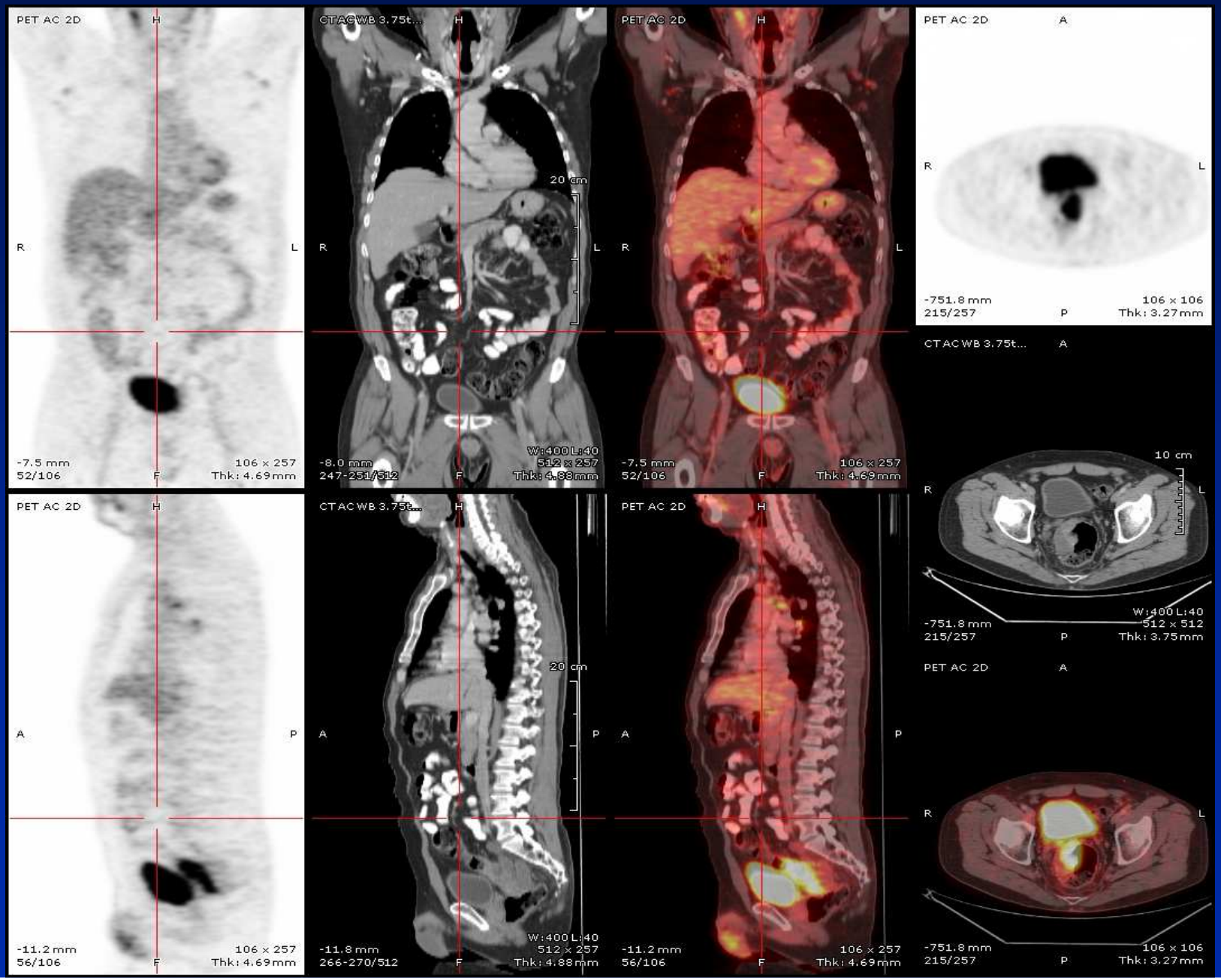

PET/CT scan in peritoneal carcinomatosis

Patient selection in GI peritoneal carcinomatosis

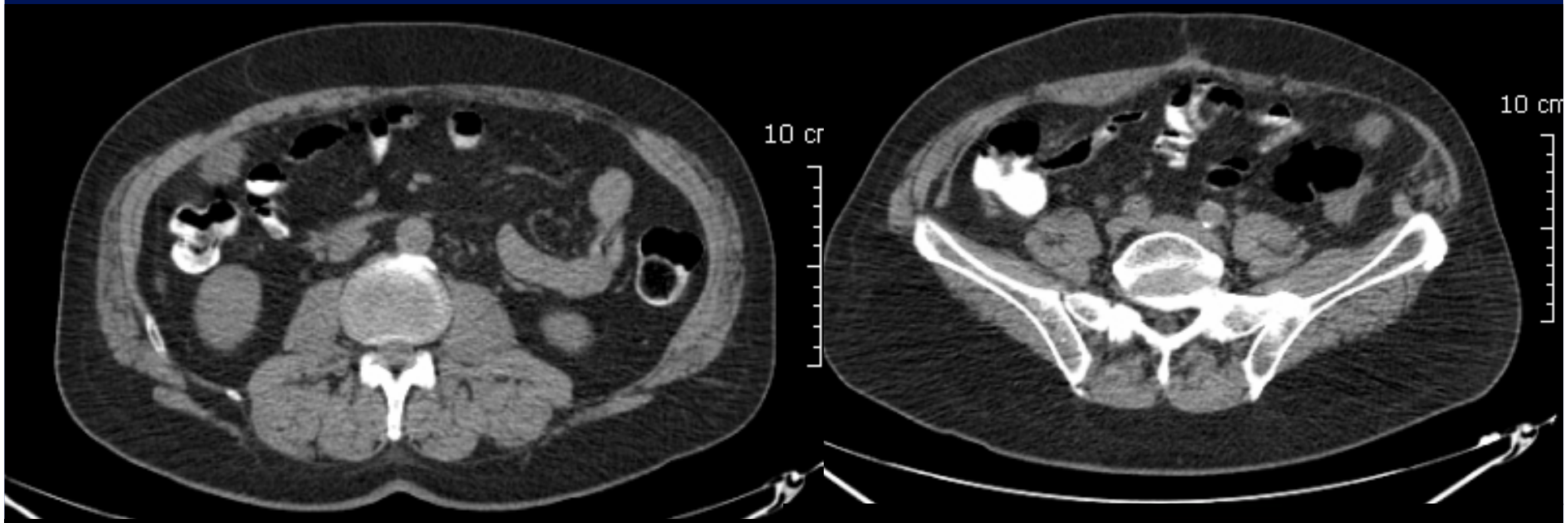

PET/CT scan in peritoneal carcinomatosis

Patient selection in GI peritoneal carcinomatosis

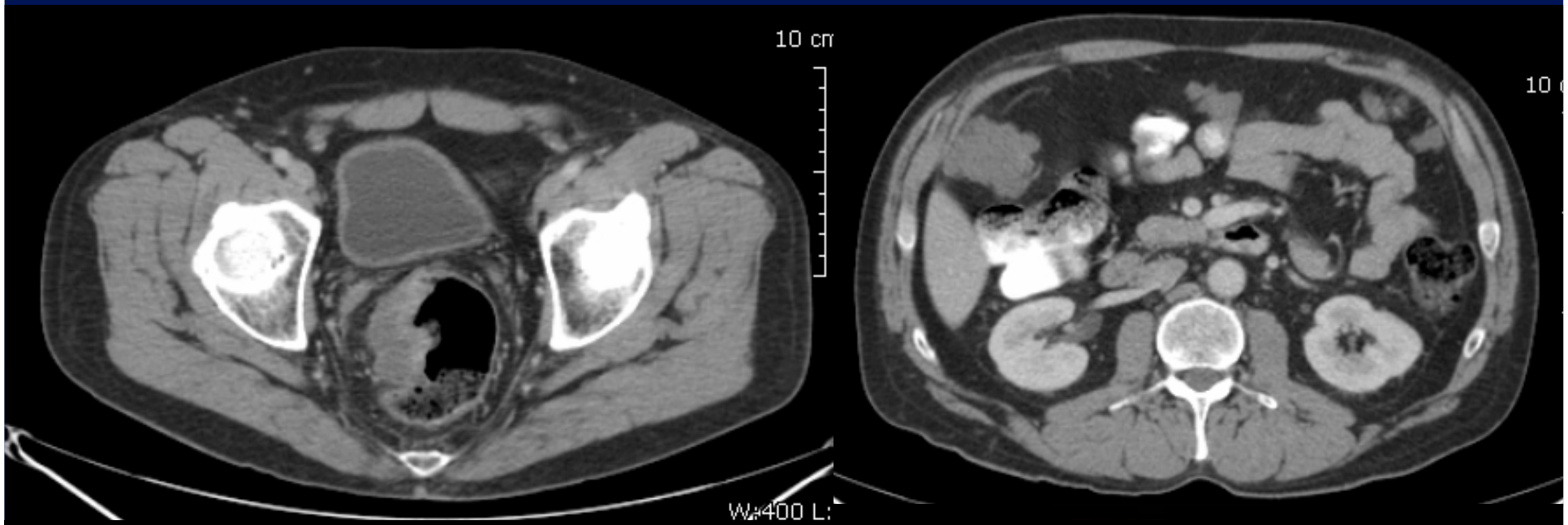

PET/CT scan in peritoneal carcinomatosis

Patient selection in GI peritoneal carcinomatosis

PET/CT scan in peritoneal carcinomatosis

Patient selection in GI peritoneal carcinomatosis
Prospective evaluation / N=30

	CT	PET/CT	Surgery
Mean PCI	5.4		10.2
Sensitivity	82 %	57 %	
Small bowel implants	26 %	0	83 %
Understimation of disease extent	70 %	80 %	

Dromain C et al. Staging of peritoneal carcinomatosis: enhanced CT vs. PET/CT. Abdom Imaging 2008; 33:87-93

PET/CT scan in peritoneal carcinomatosis

Patient selection in GI peritoneal carcinomatosis
Prospective evaluation / N=30

	CT	PET/CT	Surgery
Mean PCI	5.4		10.2
Sensitivity	82 %	57 %	
Small bowel implants	26 %	0	83 %
Understimation of disease extent	70 %	80 %	

Dromain C et al. Staging of peritoneal carcinomatosis: enhanced CT vs. PET/CT. Abdom Imaging 2008; 33:87-93

PET/CT scan in peritoneal carcinomatosis

Patient selection in GI peritoneal carcinomatosis
Prospective evaluation / N=30

Interclass Correlation

Mucinous > Non-mucinous

Mucinous = Non-mucinous

CT

PET/CT

Moderate (0.53)

Low (0.12)

SURGERY

Dromain C et al. Staging of peritoneal carcinomatosis: enhanced CT vs. PET/CT. Abdom Imaging 2008; 33:87-93

MRI in peritoneal carcinomatosis

- Outstanding soft tissue contrast

- Fat-supressed, gadolinium-enhanced SGE MRI

- Use of intraluminal contrast (diluted barium, metamucil and water)

- Ability to detect subtle peritoneal disease

Low, RS. Magnetic Resonance Imaging in the Oncology Patient: Evaluation of the extrahepatic abdomen. *Semin Ultrasound CT MRI 2005; 26:224-36*

CT vs. MRI in peritoneal carcinomatosis

	CT	MRI
Spatial resolution	Superior	Lower
Acquisition time	Short	Longer
Multiplanar imaging	Yes	Yes
Movement artifacts	No	Yes
Assessment of soft tissue	Average	Superior
Familiarity for clinicians / availability	More	Less

MRI in peritoneal carcinomatosis

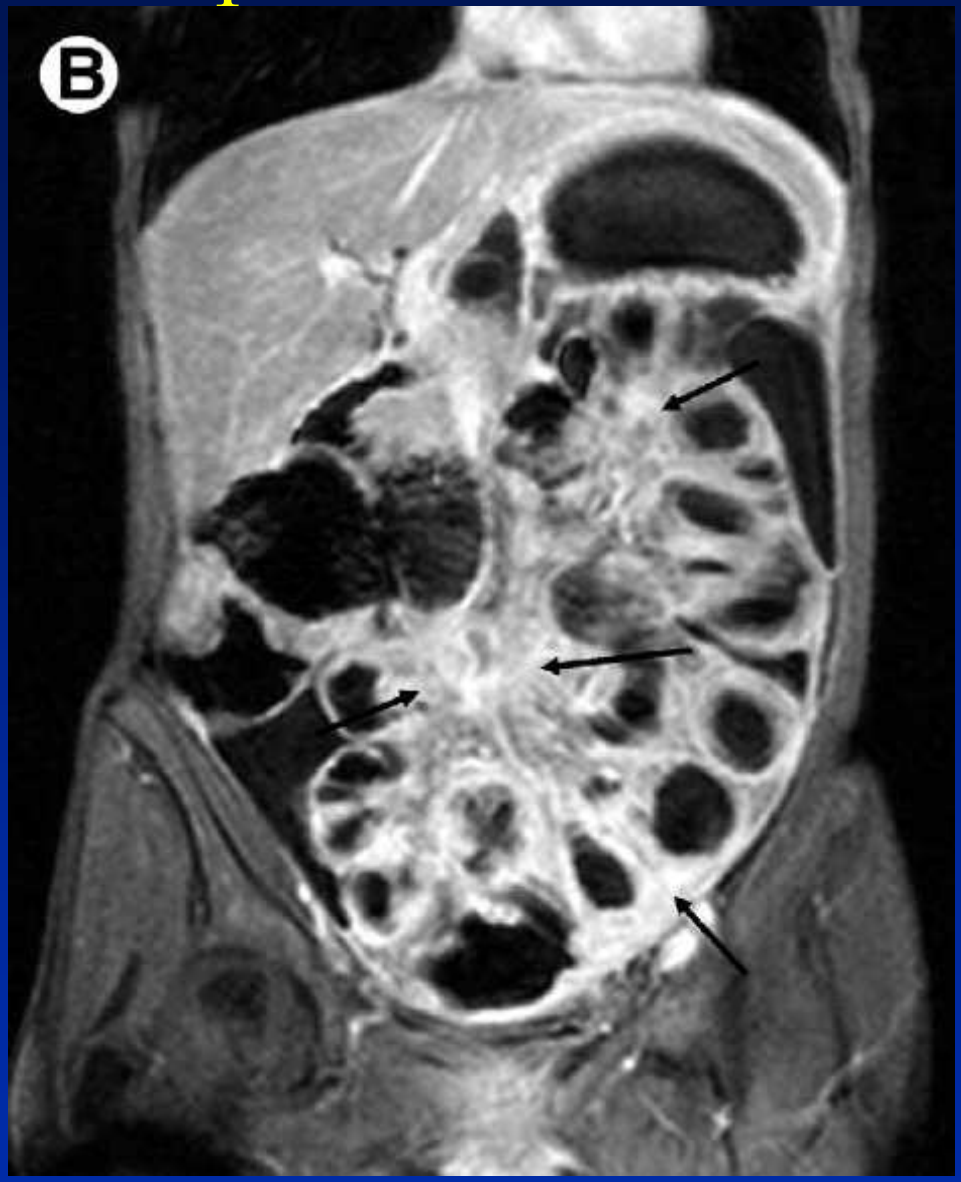

Low, RS. Magnetic Resonance Imaging in the Oncology Patient: Evaluation of the extrahepatic abdomen. *Semin Ultrasound CT MRI 2005; 26:224-36*

CT vs. MRI in peritoneal carcinomatosis

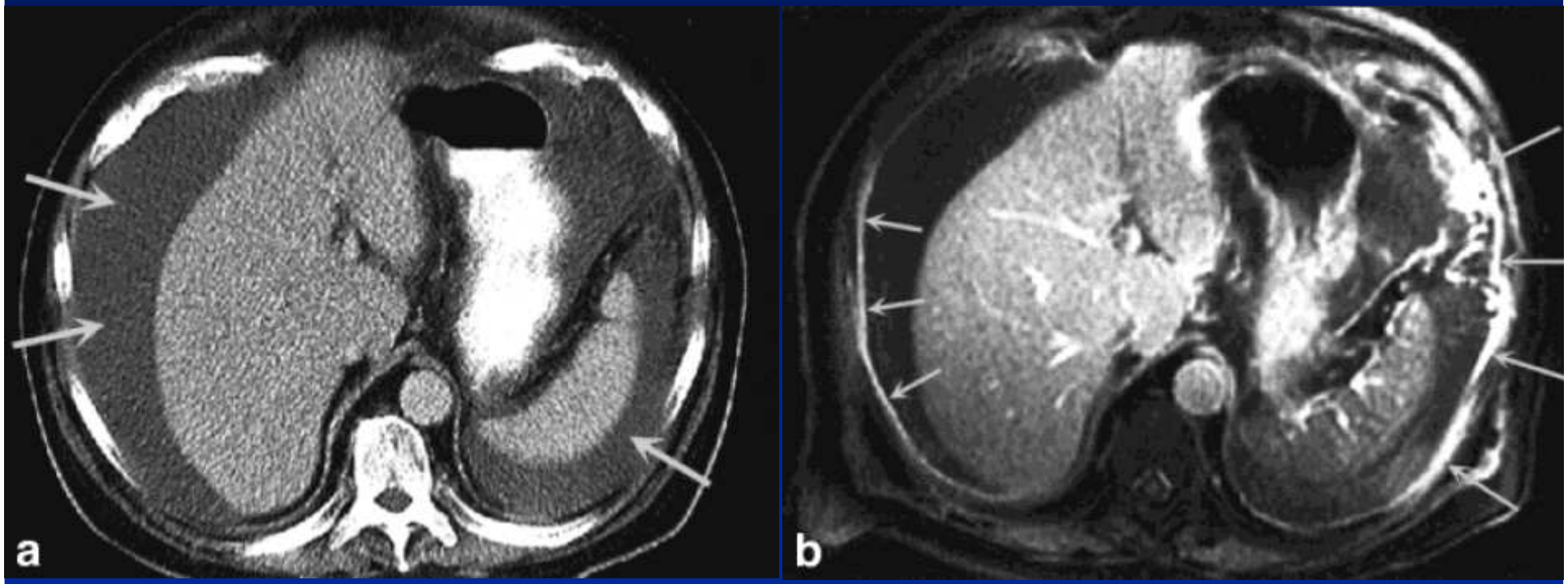

Low, RS. Extrahepatic Abdominal Imaging in Patients With Malignancy: Comparison of MR Imaging and Helical CT in 164 Patients. J. Magn. Reson. Imaging 2000;12: 269–277.

	Malignant			Benign		
	TP	FN	Sen	TP	FN	Sen
GB/biliary						
Helical CT	21	6	0.78	13	3	0.81
MRI	27	0	1.0	13	3	0.81
Pancreas						
Helical CT	26	6	0.81	1	1	0.50
MRI	30	2	0.94	2	0	1.0
Spleen						
Helical CT	9	2	0.82	9	4	0.69
MRI	9	2	0.82	9	4	0.69
Kidneys						
Helical CT	10	2	0.83	48	6	0.89
MRI	12	0	1.0	47	7	0.87
Adrenal						
Helical CT	9	0	0.82	4	0	1.0
MRI	9	0	0.82	4	0	1.0
Peritoneum						
Helical CT	21	11	0.66	1	0	1.0
MRI	32	0**	1.0	0	1	0.0
Omentum						
Helical CT	10	5	0.67	0	0	0.0
MRI	14	1	0.93	0	0	0.0
Mesentery						
Helical CT	5	9	0.36	1	0	1.0
MRI	8	6	0.57	1	0	1.0
Gastrointestinal						
Helical CT	24	14	0.63	5	1	0.83
MRI	32	6**	0.84	6	0	1.0
Retroperitoneum						
Helical CT	6	1	0.86	2	0	1.0
MRI	7	0	1.0	1	1	0.50
Abdominal wall						
Helical CT	3	2	0.60	4	2	0.67
MRI	5	0	1.0	6	0	1.0
Lymph nodes						
Helical CT	30	8	0.79	0	0	0.0
MRI	37	1	0.97	0	0	0.0
Ascites						
Helical CT	13	5	0.72	10	2	0.83
MRI	16	2	0.89	11	1	0.92
Lung bases						
Helical CT	9	2	0.82	21	4	0.84
MRI	8	3	0.83	20	5	0.80
Bones						
Helical CT	3	10	0.77	1	5	0.17
MRI	12	1*	0.92	6	0	1.0
Vascular						
Helical CT	12	10	0.55	0	0	0.0
MRI	20	2*	0.91	0	0	0.0
Pelvis						
Helical CT	10	2	0.83	2	0	1.0
MRI	11	1	0.92	2	0	1.0
Totals						
Helical CT	221	95	0.70	122	28	0.81
MR	288	28	0.91	128	22	0.85

MRI in peritoneal carcinomatosis

	Malignant			Benign		
	TP	FN	Sen	TP	FN	Sen
Peritoneum						
Helical CT	21	11	0.66	1	0	1.0
MRI	32	0**	1.0	0	1	0.0
Omentum						
Helical CT	10	5	0.67	0	0	0.0
MRI	14	1	0.93	0	0	0.0
Mesentery						
Helical CT	5	9	0.36	1	0	1.0
MRI	8	6	0.57	1	0	1.0
Gastrointestinal						
Helical CT	24	14	0.63	5	1	0.83
MRI	32	6**	0.84	6	0	1.0

MR imaging was equivalent to single-phase helical CT for depicting extrahepatic tumor at most anatomic sites and showed an advantage for depicting tumor involving the peritoneum, intestinal tract, bones and vascular structures

Low, RS. Extrahepatic Abdominal Imaging in Patients With Malignancy: Comparison of MR Imaging and Helical CT in 164 Patients. J. Magn. Reson. Imaging 2000;12: 269–277.

Yan TD et al. J Surg Oncol 2008; 98:224-7

Exam	FUNDAMENTAL	USEFUL, NOT FUNDAMENTAL	USELESS
1. Thin slice CT scan (with adequate intravenous, oral, +/- rectal contrast media)	96,77 % 100,00 %	3,23 % 0 %	0 % 0 %
2. PET total body	19,35 % 6,25 %	64,52 % 84,38 %	16,13 % 9,38 %
3. Magnetic resonance imaging	12,90 % 3,13 %	70,97 % 81,25 %	16,13 % 15,63 %

Diagnostic imaging of peritoneal carcinomatosis

"…no radiologic test is reliable for the detection of small volume of cancer that is layered out on a peritoneal surface"

Sugarbaker PH. Buillding on a consensus. J Surg Oncol 2008; 98:215-6

Diagnostic imaging of peritoneal carcinomatosis

"…no radiologic test is reliable for the detection of small volume of cancer that is layered out on a peritoneal surface"

Sugarbaker PH. Buillding on a consensus. J Surg Oncol 2008; 98:215-6

Conclusions

1. Enhanced CT of the thorax, abdomen and pelvis (oral, iv, rectal) is the current imaging standard to evaluate peritoneal surface malignancy patients for surgical exploration with the intent to perform complete cytoreductive surgery and HIPEC

2. We can expect:

- A good sensitivity for the detection of peritoneal carcinomatosis but an understimation of peritoneal disease extent

- Reasonable detection of extraperitoneal disease (complemented by PET/CT)

- Identification of key features that preclude a complete cytoreduction

- Help in planning surgical procedure

Conclusions

3. Gadolimiun-enhanced, fat-supressed MRI is a good imaging complement to CT scan for the detection of subtle peritoneal, mesenteric or bowel surface disease, but its actual clinical integration in peritoneal surface malignancy practices is yet to occur

4. The role of PET /CT is limited to the detection of extraperitoneal disease. Its role in the evaluation of peritoneal disease extent is marginal.

Imaging in peritoneal carcinomatosis

"Radiological evaluation of peritoneal surface malignancy"

Prospective comparative evaluation of CT, MRI, PET/CT against surgical findings (target n=99)

Determine the most adequate combination of imaging tests to select patients for CRS + PIC

PI: Luis Rodriguez-Bachiller, MD

AI: Luis González-Bayón, MD, PhD et al.


Radiology
Palliative Care
Medical Oncology
Clinical Nutrition
Nursing Education
Pathology
Anesthesiology
CENTRO ONCOLÓGICO
MD ANDERSON
INTERNATIONAL ESPAÑA
Peritoneal Surface Oncology Program
Surgical Oncology
Intensive Care
Hospitalization Nursing
O.R. Nursing